Dig Dis Sci (2016) 61:303–308
DOI 10.1007/s10620-015-3841-3

ORIGINAL ARTICLE

Clinical Outcome of Endoscopic Ultrasound-Guided Liver Abscess Drainage Using Self-Expandable Covered Metallic Stent (with Video)

Takeshi Ogura[1] · Daisuke Masuda[1] · Onda Saori[1] · Takagi Wataru[1] · Tatsushi Sano[1] · Atsushi Okuda[1] · Akira Miyano[1] · Masayuki Kitano[2] · Usama M. Abdel-aal[3] · Toshihisa Takeuchi[1] · Shinya Fukunishi[1] · Kazuhide Higuchi[1]

Received: 21 June 2015 / Accepted: 1 August 2015 / Published online: 9 August 2015

Abstract

Background Percutaneous drainage (PCD) is now the first-line drainage method for liver abscess because of its minimal invasiveness and high technical success rate. However, this procedure has several disadvantages, such as extra-drainage and self-tube removal. Recently, EUS-guided liver abscess drainage (EUS-AD) has been developed. However, only a few reports of EUS-AD have been reported. In addition, the clinical benefits of PCD and EUS-AD have not been reported.

Aims In the present study, the safety and feasibility of EUS-AD using fully covered SEMS (FCSEMS) and the clinical outcomes of EUS-AD and PCD were examined retrospectively.

Methods Twenty-seven consecutive patients who underwent PCD or EUS-AD between April 2012 and April 2015 were included in this study. EUS-AD was performed using FCSEMS. In addition, to prevent stent migration, 7-Fr pig tail plastic stent was placed within FCSEMS.

Results Technical success was achieved in all patients of both groups. Clinical success was 100 % in the EUS-AD group although it was 89 % in PCD group ($P = 034$). Three adverse events were seen in the PCD group (self-tube removal $n = 1$, tube migration $n = 2$), but no adverse events were seen in the EUS-AD group. The median hospital stay was significantly shorter in the EUS-AD group than in the PCD group (21 vs 41 days, $P = 0.03$).

Conclusion Because of the short hospital stay, the high clinical success rate, and the low adverse event rate compared to PCD, EUS-AD has potential as a first-line treatment for liver abscess.

Keywords Liver abscess · Endoscopic ultrasound-guided liver abscess drainage · Endoscopic ultrasound-guided fine-needle aspiration · Endoscopic ultrasound-guided drainage · Interventional EUS · Endoscopic ultrasound

Introduction

Liver abscesses sometimes require not only antibiotic agent treatment, but also drainage, such as percutaneous drainage (PCD) or aspiration [1, 2] or surgical drainage [3]. Surgical drainage is indicated for multiple abscesses or failed PCD, but this procedure is invasive and has relatively high mortality and morbidity rates [4, 5]. On the other hand, PCD is now the first-line drainage method for liver abscess because of its minimal invasiveness and high technical success rate [1, 2]. However, this procedure has several disadvantages, such as extra-drainage and self-tube removal.

Recently, interventional treatment using endoscopic ultrasound (EUS), such as biliary drainage [6] or pancreatic duct drainage [7], has been developed. In the same manner, EUS-guided liver abscess drainage (EUS-AD) has been developed [8]. This procedure may have several advantages, such as internal drainage and indicated in ascites patients,

Electronic supplementary material The online version of this article (doi:10.1007/s10620-015-3841-3) contains supplementary material, which is available to authorized users.

✉ Takeshi Ogura
oguratakeshi0411@yahoo.co.jp

[1] 2nd Department of Internal Medicine, Osaka Medical College, 1-1 Daigakuchou, Takatsukishi, Osaka 464-8681, Japan

[2] Department of Gastroenterology and Hepatology, Kinki University Faculty of Medicine, Osaka-sayama, Japan

[3] Division of Gastroenterology, Department of Internal Medicine, Sohag University, Sohag, Egypt

compared with PCD. However, only a few case reports or case series of EUS-AD have been reported [8–16]. In addition, the clinical benefits of PCD and EUS-AD have not been reported. Moreover, few cases of EUS-AD using self-expandable metallic stents (SEMSs) have been reported [13–16].

In the present study, the safety and feasibility of EUS-AD using fully covered SEMS (FCSEMS) and the outcomes of EUS-AD and PCD were examined retrospectively.

Materials and Methods

Patients

Consecutive patients with a liver abscess that needed drainage at Osaka Medical College between April 2012 and April 2015 were enrolled. Liver abscess was diagnosed by typical imaging, clinical symptoms such as abdominal pain and fever, and elevated markers of inflammation on blood examination.

In our institute, the first-line drainage method for liver abscess was PCD. Indications for EUS-AD were: (1) presence of ascites; (2) possibility of self-tube removal due to dementia; or (3) absence of a safe puncture route for the PCD procedure. All patients were given antibiotics before undergoing any procedures, and all patients underwent computed tomography (CT) the day after EUS-AD. Patients provided their written informed consent for all procedures associated with the study.

Technical Tips for Percutaneous Liver Abscess Drainage

PCD was performed by one experienced physician (D.M.) who was trained in percutaneous biliary drainage (PTCD). Liver abscesses were detected at a frequency of 5.0 MHz using a convex transducer under ultrasonographic guidance. The liver abscess was then punctured using an 18-G FNA needle, and necrotic material was aspirated. The contrast medium was injected, and a 0.035-inch guidewire was inserted into the cavity of the liver abscess. Finally, an 8-Fr pig tail drainage tube was placed within the liver abscess. If the clinical effect was insufficient, the drainage tube size was increased up to 10 Fr.

Technical Tips for EUS Drainage of Liver Abscess (Video)

EUS-AD was performed by one therapeutic endoscopist (T.O.) who was trained and experienced in both EUS and endoscopic retrograde cholangiopancreatography (ERCP). The liver abscess was visualized at a frequency of 7.5 MHz using a convex echoendoscope (GF-UGT260; Olympus Optical, Tokyo, Japan) connected to an ultrasound device (SSD5500; Aloka, Tokyo, Japan). If the liver abscess was located in the left lobe, puncture was performed mainly from the stomach. If the liver abscess was located in the right liver lobe, EUS-AD was performed from the duodenum. After the liver abscess was identified, it was punctured using a 19-G FNA needle (Sono Tip Pro Control 19G; Medi-Globe GmbH, Rosenheim, Germany or Medico's Hirata, Osaka, Japan) using Doppler ultrasonography to avoid any intervening vessels (Fig. 1a). Necrotic material was aspirated, and a small amount of the contrast medium was injected (Fig. 1b). Then, the 0.025-inch guidewire (VisiGlide; Olympus Medical Systems, Tokyo, Japan) was coiled within the liver abscess (Fig. 1c). Next, the ERCP cannula was exchanged to dilate the fistula. If SEMS insertion into the liver abscess was difficult, dilation was performed using a 4-mm balloon catheter (ZARA®, EPBD balloon catheter, Century Medical, Inc., Japan). The metallic stent delivery system was inserted into the liver abscess, and an FCSEMS (BONA stent, Standard Sci Tech Inc, Seoul, Korea, 10 mm × 6, 8 cm, or Niti-S Covered Metallic stent 10 mm × 12 cm, TaeWoong Medical, Seoul, Korea) was placed from the liver abscess to the stomach or duodenum (Fig. 1d, e). Finally, we inserted 7-Fr pig tail plastic stent within FCSEMS to prevent stent migration. If the clinical effect was insufficient, aspiration of necrotic material was performed under endoscopic guidance. Figure 2 showed CT imaging of pre- and post EUS-AD.

Definitions

The maximum size of the liver abscess was measured by CT imaging. Technical success was defined as successful placement of the PCD tube or EUS-AD stent. Clinical success was also defined as complete resolution of clinical symptoms, such as abdominal pain and fever, or decreased inflammation on blood examination within 14 days after each procedure. Recurrence of liver abscess after each procedure was defined as the typical symptoms with imaging findings. The follow-up period was measured from the day of performing PCD or EUS-AD to the final observation. Hospital stay was calculated from the day of each procedure to the day of each patient's discharge. Adverse events were defined according to the American Society for Gastrointestinal Endoscopy lexicon's severity grading system [17].

Results

Patients' Characteristics

In this study, 27 patients with a liver abscess were enrolled. Table 1 shows the patients' characteristics. PCD was

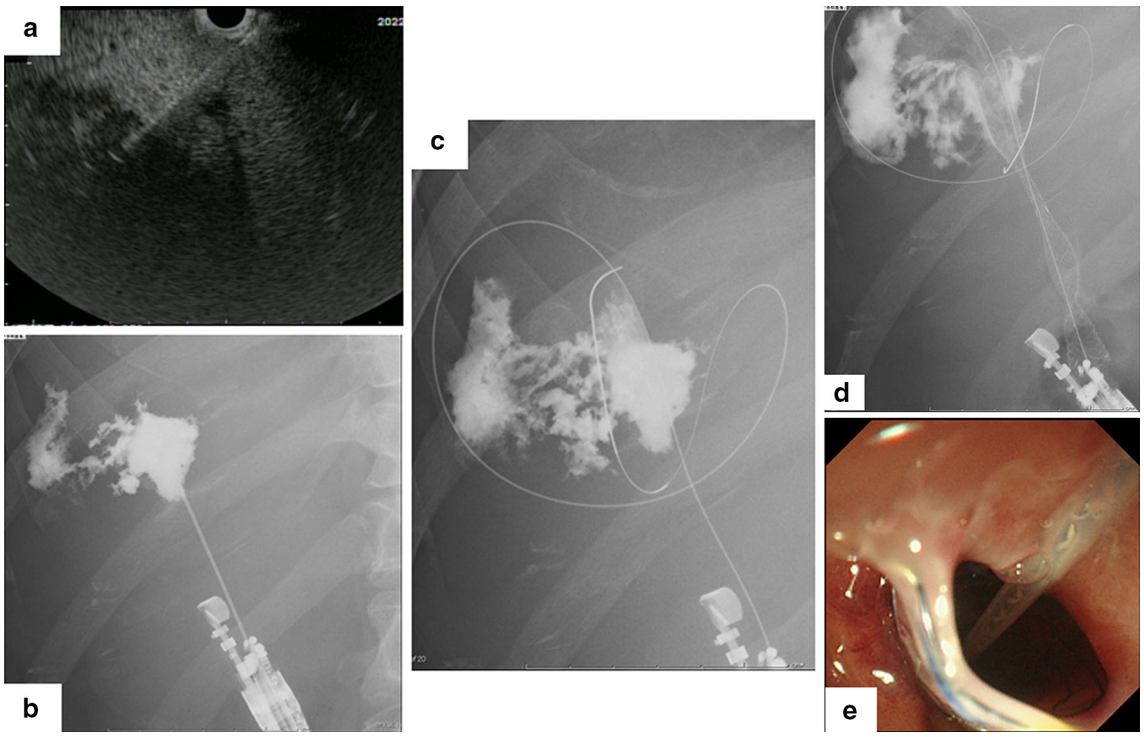

Fig. 1 **a** Liver abscess was punctured using 19G FNA needle. **b** The contrast medium was injected through FNA needle. **c** 0.025-inch guidewire was inserted into liver abscess cavity. **d** Fully covered self-expandable metallic stent was placed from liver abscess to the duodenum. **e** Endoscopic image of EUS-AD

Fig. 2 **a** Huge liver abscess was seen in *right lobe*. **b** Size of liver abscess was decreased after 1 week from EUS-AD. **c** Fully covered self-expandable metallic stent and pig tail plastic stent were placed

performed for 19 consecutive patients (median age 66.0 years, range 46–85 years; 16 males, three females), and EUS-AD was performed for eight patients (median age 66.5 years, range 31–84 years; four males, three females). The location of the liver abscess was left in 12 and right in seven in the PCD group, and left in six and right in two in the EUS-AD group ($P = 0.56$). Median abscess size was not significantly different between PCD and EUS-AD (73.7 vs 74.6 mm, $P = 0.59$). On blood examination, the mean white blood cell (WBC) count was 14371.4/μl, and the mean C-reactive protein (CRP) was 16.3 mg/dl in the PCD group, and the mean WBC count was 13229.0/μl and the mean CRP was 10.4 mg/dl in the EUS-AD group, with no significant differences. Relatively long-term follow-up (PCD median 268 days, EUS-AD 218 days; $P = 0.09$) was performed.

The indications for EUS-AD were: (1) risk of self-tube removal, $n = 5$; (2) ascites, $n = 2$; and (3) recurrence of liver abscess after PCD tube removal, $n = 1$. The source of the infections was: *Klebsiella pneumonia* ($n = 9$), unknown ($n = 12$), *Escherichia coli* ($n = 4$), *Salmonella* (n = 1), and *Amebiasis* (n = 1).

Overall Outcomes of Percutaneous and EUS-Guided Liver Abscess Drainage

Table 2 shows the overall outcomes of percutaneous and EUS-guided liver abscess drainage. Technical success was achieved in all patients of both groups. Clinical success was obtained in all patients in the EUS-AD group. However, in the PDC group, effective drainage could not be obtained in two patients. One patient had a huge liver abscess (99.28 mm, caused by salmonella) and sepsis, and 25 days after the PCD procedure, this patient died. Another patient had advanced malignant cancer, and effective drainage could not be obtained. The median number of procedures was not significantly different between the two groups. On the other hand, three adverse events were seen in the PCD group (self-tube removal $n = 1$, tube migration $n = 2$), but no adverse events were seen in the EUS-AD group.

Table 1 Patients' characteristics

	PCD $n = 19$	EUS-AD $n = 8$	*P* value
Median age (range), year	66 (46–85)	66.5 (31–84)	0.40
Sex (male/female)	16:3	4:3	0.15
Location			
Left lobe	12	6	0.56
Right lobe	7	2	
Median abscess size (mm, range)	73.7 (32.8–144.4)	74.6 (61.9–99.3)	0.59
Mean WBC count (μl)	14371.4	13229.0	0.15
Mean CRP (mg/dl)	16.3	10.4	0.84
Median observation period, days (range)	268 (17–1081)	218 (17–396)	0.09

Table 2 Overall outcomes of PCD and EUS-AD

	PCD $n = 19$	EUS-AD $n = 8$	*P* value
Technical success % (*n*)	100 (19/19)	100 (8/8)	–
Clinical success % (*n*)	89 (17/19)	100 (8/8)	0.34
Median number of procedures (range)	1 (1–4)	1.5 (1–2)	0.35
Mean post-WBC count (μl)	9716.2	8822.5	
Mean post-CRP (mg/dl)	7.82	7.12	
Adverse event			
Total number	3	0	0.30
Adverse events			
Self-tube removal	1		
Stent migration	2		
Median hospital stay, days (range)	41 (17–187)	21 (11–200)	0.03
Recurrence of liver abscess (*n*)	1	0	0.60

Table 3 Summary of EUS-guided liver abscess drainage

References	Number	Location (*n*)	Approach route (*n*)	Stent	Technical success (%)	Clinical success (%)	Adverse events
Seewald et al. [8]	1	Left lobe	Gastric	7-Fr ENCD	100 (1/1)	100 (1/1)	None
Ang et al. [9]	1	Left lobe	Gastric	8-, 10-Fr pig tail PS	100 (1/1)	100 (1/1)	None
Noh et al. [10]	3	Caudate lobe (2) Left lobe (1)	Gastric (2) Duodenal (1)	7-Fr pig tail PS 7-Fr ENCD	100 (3/3)	100 (3/3)	None
Itoi et al. [11]	2	Caudate lobe (1) Left lobe (1)	Gastric (1) Duodenal (1)	7-Fr straight and pig tail PS 5-Fr ENCD	100 (2/2)	100 (2/2)	None
Keohane et al. [12]	2	Caudate lobe (2)	Gastric (2)	7-Fr pig tail PS 10-Fr pig tail PS	100 (2/2)	100 (2/2)	None
Medrado et al. [13]	1	Left lobe	Gastric	10 mm × 6 cm, FCSEMS	100 (1/1)	100 (1/1)	Stent migration
Alcaide et al. [14]	1	Left lobe	Gastric	LASEMS	100 (1/1)	100 (1/1)	None
Kawakami et al. [15]	1	Left lobe	Gastric	LASEMS	100 (1/1)	100 (1/1)	None
Tonozuka et al. [16]	7	Left lobe (6) Right lobe (1)	Gastric (6) Duodenal (1)	LASEMS (2) FCSEMS (5)	100 (7/7)	71.4 (5/7)	None

ENCD endoscopic nasocystic drainage, *PS* plastic stent, *FCSEMS* fully covered self-expandable metallic stent, *LASEMS* lumen apposing self-expanding metallic stent

The median hospital stay was significantly shorter in the EUS-AD group than in the PCD group (21 vs 41 days, $P = 0.03$).

During follow-up, recurrence of the liver abscess was seen in one patient. This patient underwent PCD, and effective drainage was obtained. However, 6 months after tube removal, recurrence of the liver abscess was seen, and EUS-AD was performed. This patient underwent clinical follow-up for 6 months, with no recurrence of the liver abscess.

Discussion

The gold-standard treatment for liver abscess is PCD, and the technical success rate of this procedure has been reported to range from 85 to 95 % [18, 19]. However, the disadvantages of this procedure are extra-drainage and self-tube removal, and these adverse events may lead to patient discomfort. On the other hand, EUS-AD, a novel drainage procedure, has been reported. In the present study, the technical and functional success rates of EUS-AD were extremely high, and the rate of adverse events was low compared with PCD. In addition, the hospital stay was shorter in the EUS-AD group than in the PCD group. Compared with PCD, EUS-AD has several advantages, including initial internal drainage, so that the risk of self-tube removal is not present. In addition, the patient's quality of life is maintained. In addition, clear visualization of the internal vessels can be obtained by color Doppler ultrasound [11], and transcutaneous infection can be avoided. If the stent of EUS-AD is present without removal, it is difficult for a liver abscess to occur, although this should be confirmed by long-term follow-up.

However, in EUS-guided transluminal drainage, use of a metallic stent is one of the important points. First, if a plastic stent is used in EUS-guided transluminal drainage, the contents of the drainage area may leak into the abdominal cavity. Since a plastic stent is thin compared with a metallic stent, the contents of the drainage area may flow through the stent and drainage area or through the abscess wall [6]. On the other hand, SEMSs are expandable and have a large diameter, resulting in impaction between the stent and the surrounding drainage area or abscess wall. Second, a metallic stent has a large diameter ($\sim$ >30 Fr) that is clinically useful because it can provide an excellent drainage effect compared with a PCD tube.

Table 3 shows previous reports of EUS-AD using metallic stents. To date, only a few case reports or case series of EUS-AD have been reported [8–16]. In addition, only ten cases of EUS-AD using an SEMS have been reported [13–16]. According to these reports, technical success was obtained in all patients, and clinical success rates of EUS-AD ranged from 71.4 to 100 %. The approach route was from the stomach in 16 and the duodenum in three. Liver abscesses are usually located in the left or caudate lobe. Indeed, EUS-guided transluminal drainage for the right hepatic bile duct [20] or the right lobe is technically difficult. With EUS-AD, only one case of a right liver abscess has been reported [16]. On the other hand, in the present study, two cases of right liver abscess were included. To visualize the right lobe, the echoendoscope was introduced into the duodenum. First, the

common bile duct was identified, and then, the hepatic hilum was identified using counterclockwise rotation. Next, using the echoendoscope's right–left angle, echo-imaging, and radiographic guidance, the right hepatic lobe was identified. In this procedure, EUS was moved extremely slowly and softly to avoid duodenal perforation. However, this technique cannot be usually performed; therefore, it is one of the limitations of EUS-AD for right hepatic lobe.

Among the reports of EUS-AD using an SEMS, stent migration was seen as an adverse event. This fact suggested that if EUS-AD was performed from the stomach, especially the upper stomach, there is a possibility of stent migration as in EUS-guided hepaticogastrostomy (EUS-HGS). To prevent this adverse event, the tips of the EUS-AD should be as for EUS-HGS and a long SEMS should be selected [21, 22]. Recently, a novel SEMS with anti-migration properties and a large diameter has become available [14–16]. This SEMS has a definite clinical impact, but also several limitations. First, stent migration cannot be completely prevented. Indeed, stent migration occurred in a case of pancreatic fluid collection drainage [23]. Therefore, in cases with a possibility of stent migration, the stent in stent method (pig tail stent within SEMS) may be useful. Second, if the distance between the liver abscess and the intestinal wall which was punctured was far, this stent could not be used. For these reasons, we selected long FCSEMSs.

In the light of these previous reports, although our study was retrospective with a single operator, the present study was important because of the relatively large case series, and it is the first to compare the clinical outcomes between EUS-AD and PCD.

In conclusion, because of the short hospital stay, the high clinical success rate, and the low adverse event rate compared to PCD, EUS-AD has potential as a first-line treatment for liver abscess, although a prospective, randomized, controlled study is needed.

Compliance with ethical standards

Conflict of interest None.

References

1. Yu CHS, Ho SMS, Lau WY, et al. Treatment of pyogenic liver abscess: prospective randomized comparison of catheter drainage and needle aspiration. *Hepatology*. 2004;4:932–938.
2. Zerem E, Hadzic A. Sonographically guided percutaneous catheter drainage versus needle aspiration in the management of pyogenic liver abscess. *AJR. Am J Roentegnol*. 2007;3:W138–W142.
3. Tan YM, Chung YFA, Chow KHP, et al. An appraisal of surgical and percutaneous drainage for pyogenic liver abscesses lager than 5cm. *Ann Surg*. 2005;3:485–490.
4. Huang CJ, Pitt HA, Lipsett PA, et al. Pyogenic hepatic abscess. Changing trends over 42 years. *Ann Surg*. 1996;223:600–609.
5. Rahimian J, Wilson T, Orman V, et al. Pyogenic liver abscess: recent trends in etiology and mortality. *Clin Infect Dis*. 2004; 11:1654–1659.
6. Ogura T, Higuchi K. Dose endoscopic ultrasound-guided biliary drainage really have clinical impact? *World J Gastroenterol*. 2015;28:1049–1052.
7. Itoi T, Yasud I, Kurihara T, et al. Technique of endoscopic ulrasonography-guided pancreatic duct intervention (with videos). *J Hepatobiliary Pancreat Sci*. 2014;21:E4–E9.
8. Seewald S, Imazu H, Omar S, et al. EUS-guided drainage of hepatic abscess. *Gastrointest Endosc*. 2005;61:495–498.
9. Ang TL, Seewald S, Teo EK, et al. EUS-guided drainage of ruptured liver abscesses. *Endoscopy*. 2009;41:E21–E22.
10. Noh SH, Park do H, Kim YR, et al. EUS-guided drainage of hepatic abscesses not accessible to percutaneous drainage (with videos). *Gastrointest Endosc*. 2010;71:1314–1319.
11. Itoi T, Ang T, Seewald S, et al. Endoscopic ultrasonography guided drainage for tuberculous liver abscess drainage. *Dig Endosc*. 2011;23:158–161.
12. Keohane J, DiMaio CJ, Schattner MA, et al. EUS guided transgastric drainage of caudate lobe liver abscess. *J Interv Gastroenterol*. 2011;1:139–141.
13. Medrado BF, Carneiro FO, Vilaça TG, et al. Ensoscopic ultrasound-guided drainage of giant liver abscess associated with transgastric migration of self-expandable metallic stent. *Endoscopu*. 2013;45:E331–E332.
14. Alcaide N, Vargas-Garcia AL, de la Serna-Higuera C, et al. EUS-guided drainage of liver abscess by using a lumen-apposing metal stent (with video). *Gastrointest Endosc*. 2013;78:941–942. **(discussion 942)**.
15. Kawakami H, Kawakubo K, Kuwatani M, et al. Endoscopic ultrasound-guided liver abscess drainage using a dedicated, wide, fully covered self-expandable metallic stent with flared-ends. *Endoscopy*. 2014;46:E982–E983.
16. Tonozuka R, Itoi T, Tsuchiya T, et al. EUS-guided drainage of hepatic abscess and infected biloma using short and long metal stent (with videos). Gastrointest Endosc. Epub. 04/02/2015.
17. Cotton PB, Eisen GM, Aabakken L, et al. A lexicon for endoscopic adverse event: report of an ASGE workshop. *Gastrointest Endosc*. 2010;71:446–454.
18. Onder A, Kapan M, Böyük A, et al. Surgical management of pyogenic liver abscess. *Eur Rev Med Pharmacol Sci*. 2011;15: 1182–1186.
19. Ferraioli G, Garlaschelli A, Zanaboni D, et al. Percutaneous and surgical treatment of pyogenic liver abscesses: observation over a 21-year period in 148 patients. *Dig Liver Dis*. 2008;40:690–696.
20. Ogura T, Sano S, Onda S, et al. Endoscopic ultrasound-guided biliary drainage for right hepatic bile duct obstruction: novel technical tips. *Endoscopy*. 2015;47:72–75.
21. Ogura T, Masuda D, Imoto A, et al. Novel method of endoscopic ultrasound-guided hepacticogastrostomy to prevent for stent migration. *J Gastroenterol Hepatol*. 2014;29:1815–1821.
22. Itoi T, Isayama H, Sofuni A, et al. Stent selection and tips on placement technique of EUS-guided biliary drainage: transduodenal and transgastric stenting. *J Hepatobiliary Pancreat Sci*. 2011;18:664–672.
23. Bapaye A, Itoi T, Kongkam P, et al. New fully covered large-bore wide-flare removable metal stent for drainage of pancreatic fluid collections: results of a multicenter study. *Dig Endosc*. 2015; 27:499–504.